



Surrey Total Health
Your Health. Our Reputation.

The Young and Old of Knees

Mr Joshua Jacob

Consultant Orthopaedic Surgeon

Specialist in Hip and knee, Sports injuries of knee, Complex
Trauma

Disclosures



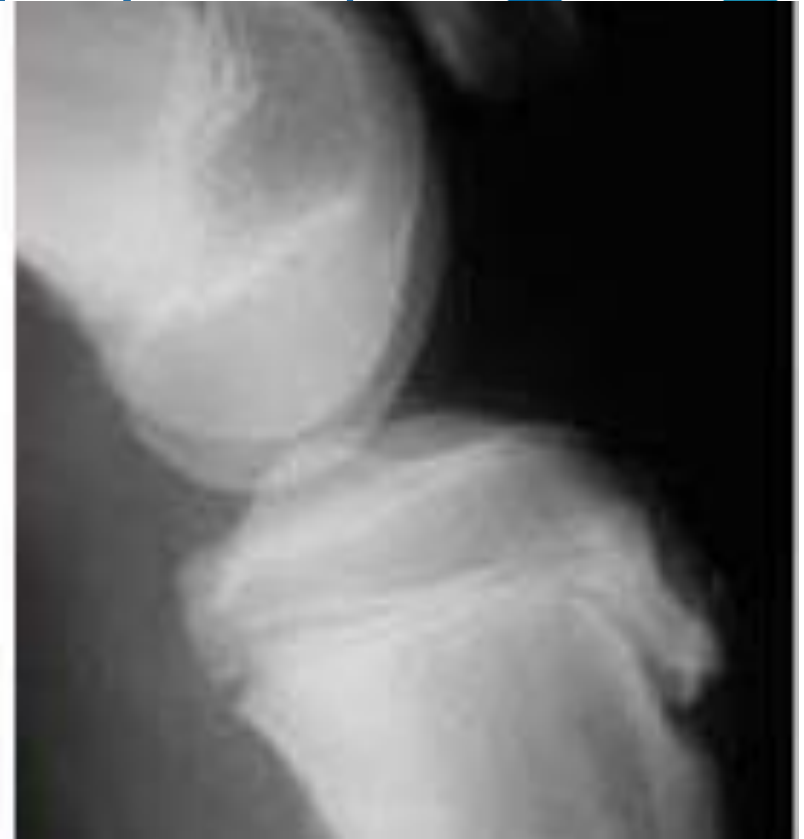
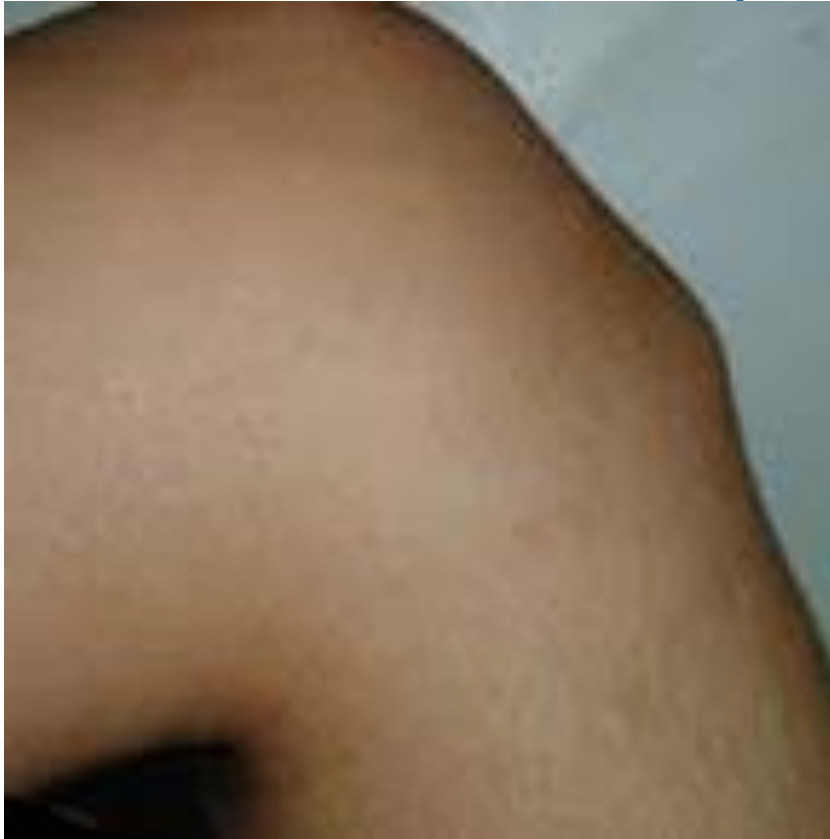MONDAY

15yr old boy – with Mum



- Keen sprinter and volleyball player
- Has had a recent growth spurt
- Pain on anterior aspect of knee
- Exacerbated by kneeling
- Tender over tibial tubercle
- Pain on resisted knee extension

Osgood Schlatter's Disease (Tibial Tubercle Apophysitis)



Osgood Schlatter's Disease (Tibial Tubercle Apophysitis)



- RICE (+NSAIDS)
- Activity modification
- Knee sleeve
- If no improvement – Refer to Orthopaedic Surgeon
- POP cast x 6 weeks
- Excision of ossicle

Differential of Osgood's



- Sinding-Larsen-Johansson syndrome (chronic apophysitis of inferior pole of patella)
- Osteochondroma of proximal tibia
- Tibial tubercle #

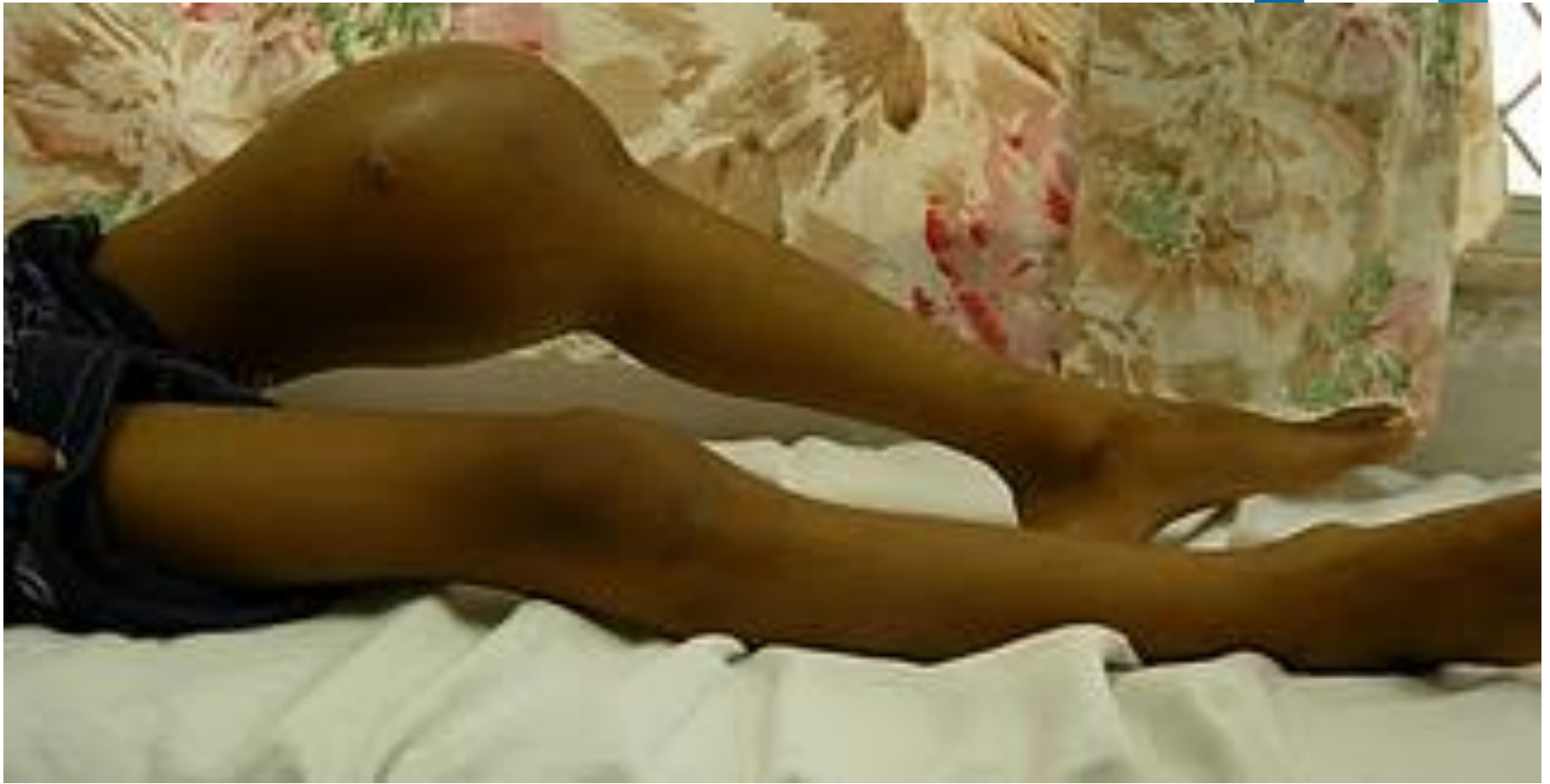TUESDAY

20 yr old boy 2nd yr in University



- Painful knee
- Had a collision whilst playing football for his Uni
- Extremely swollen and tender knee
- Warm++

20 yr old boy 2nd yr in University



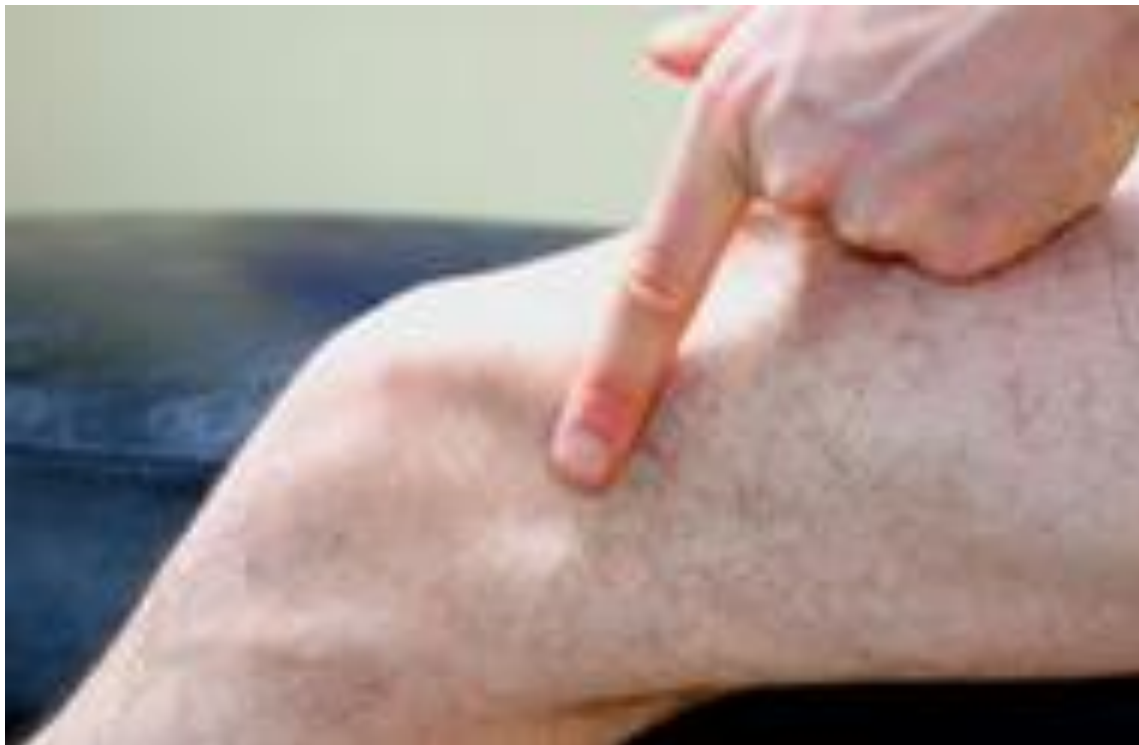Osteosarcoma



- Refer immediately
- ****Do not Aspirate****
- Xrays, Staging CR, Bone scan
- Tumour unit –multi-agent chemotherapy (pre-op for 8-12 weeks + limb salvage resection + post op for 6-12months)

WEDNESDAY

35yr old, banker, Marathon runner



35yr old, banker, Marathon runner



- Recent increase in training
- Has not changed his running shoes for a year
- Pain exacerbated by change in running terrain
- Usually relieved by resting on w/e
- Tender over Great Trochanter
- Ober's Test

ITB friction syndrome

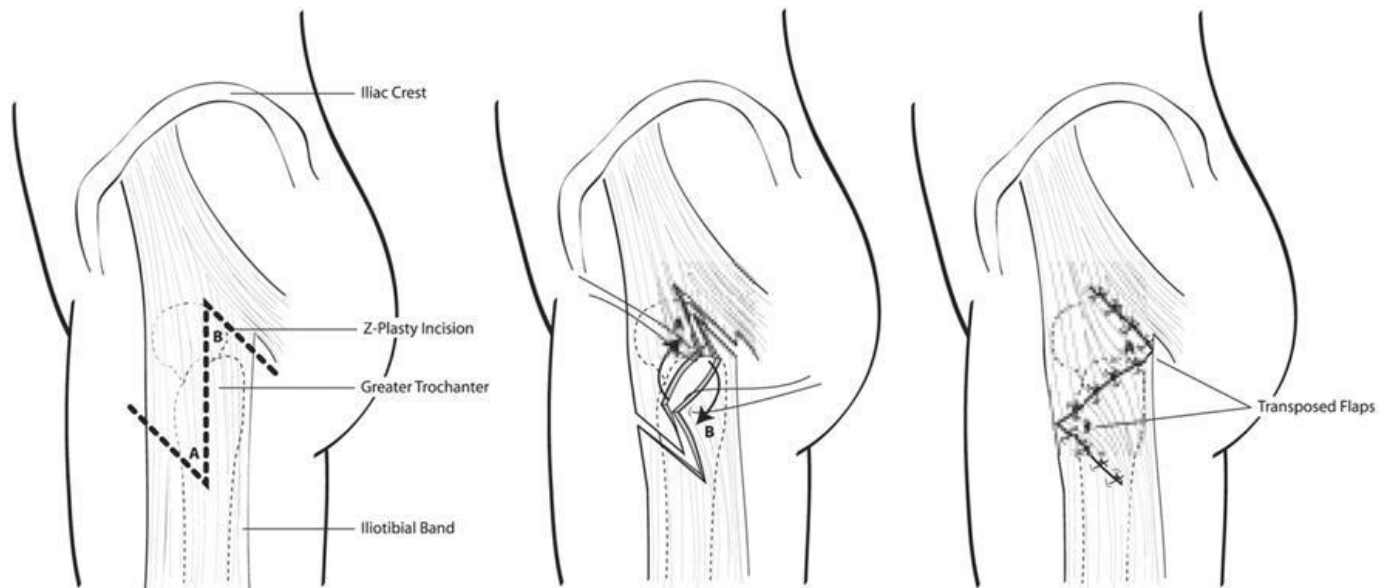


- RICE
- NSAIDS
- Steroid injection (40mg Depomederone + 0.5% Marcaine)
- Physiotherapy – deep friction massage, hip abductors
- Refer to Orthopaedic Surgeon

ITB friction syndrome – Surgical Rx



- Arthroscopy
- Surgical excision of ellipse of ITB
- Z plasty (refractory cases)

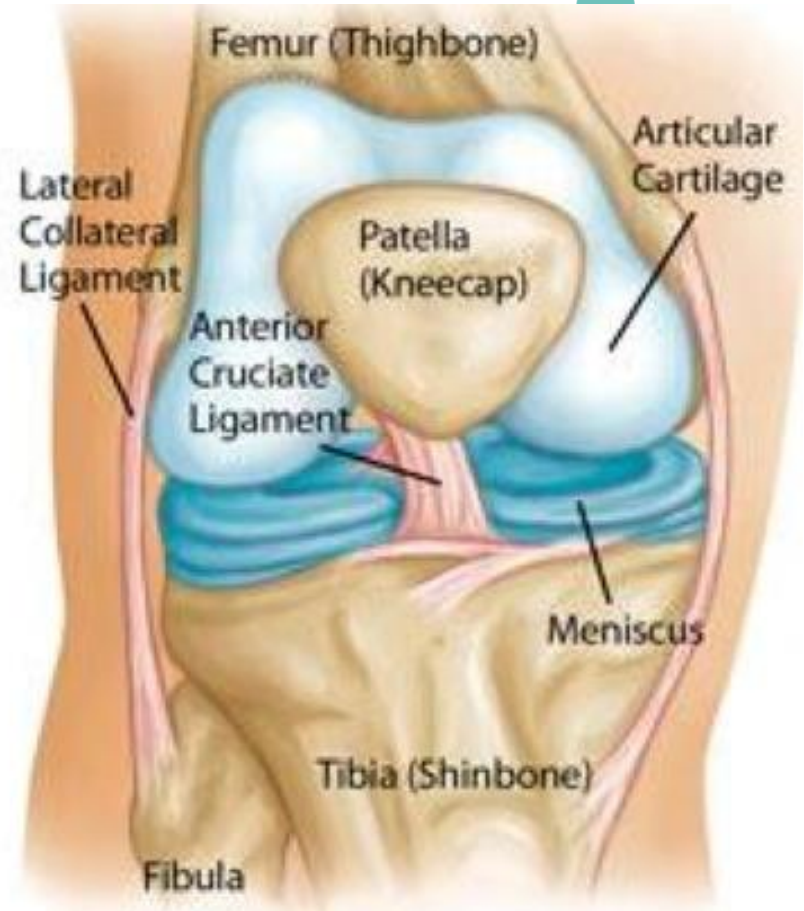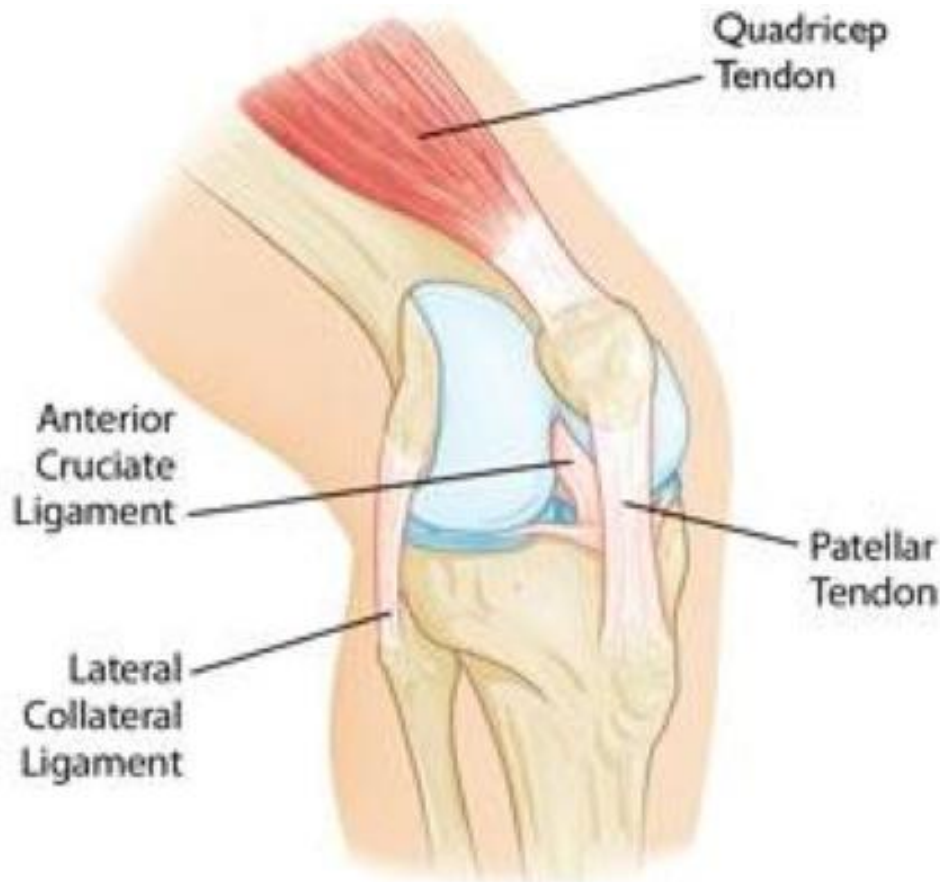


24 FY1 doctor

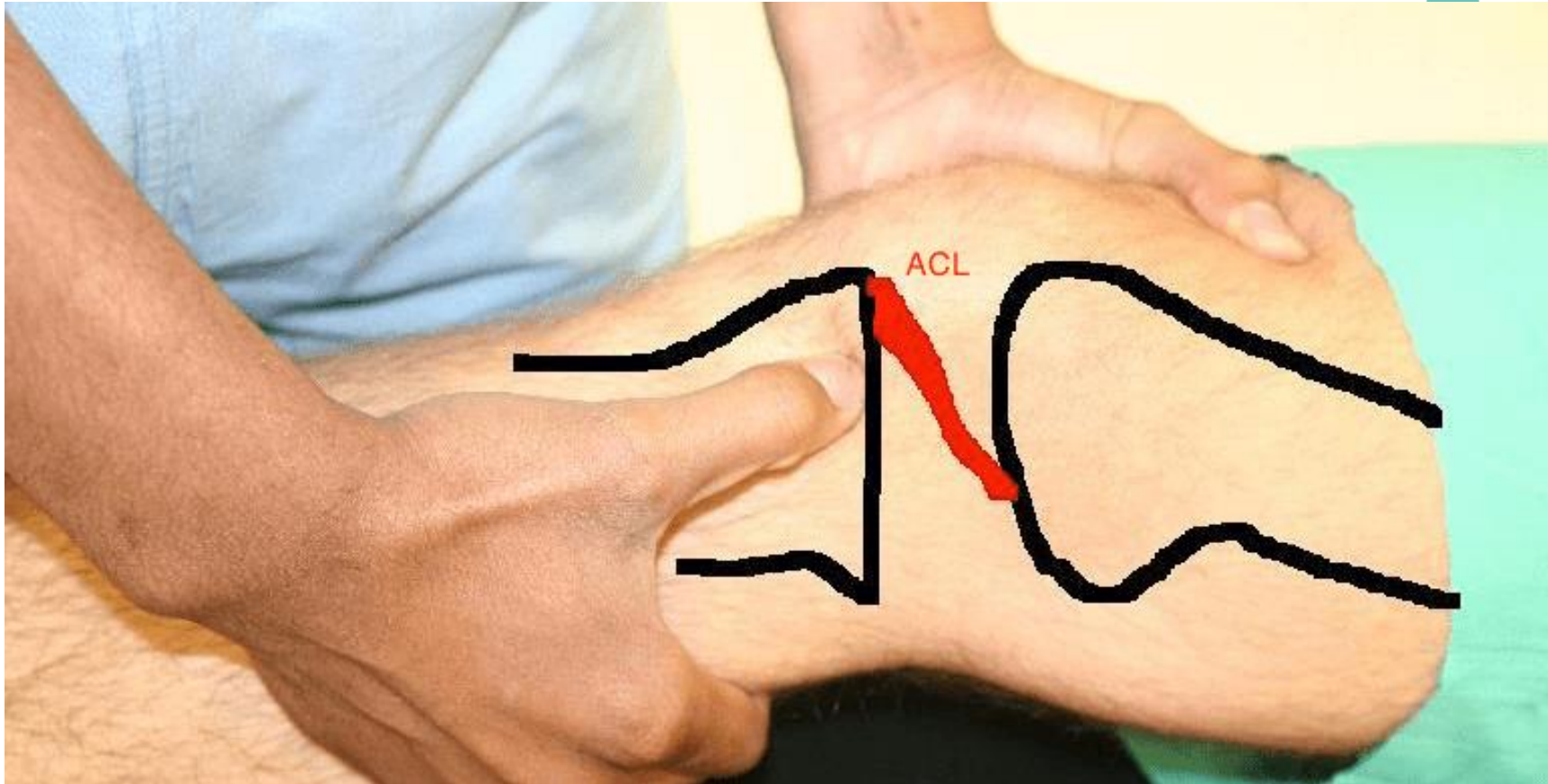


- Painful + immediately swollen right knee after rugby tackle
- Non contact injury
- Knee gave way after a 'cutting' movement
- Heard an audible "pop"
- Carried off the field

ACL injury - Anatomy



ACL injury – Lachman's test

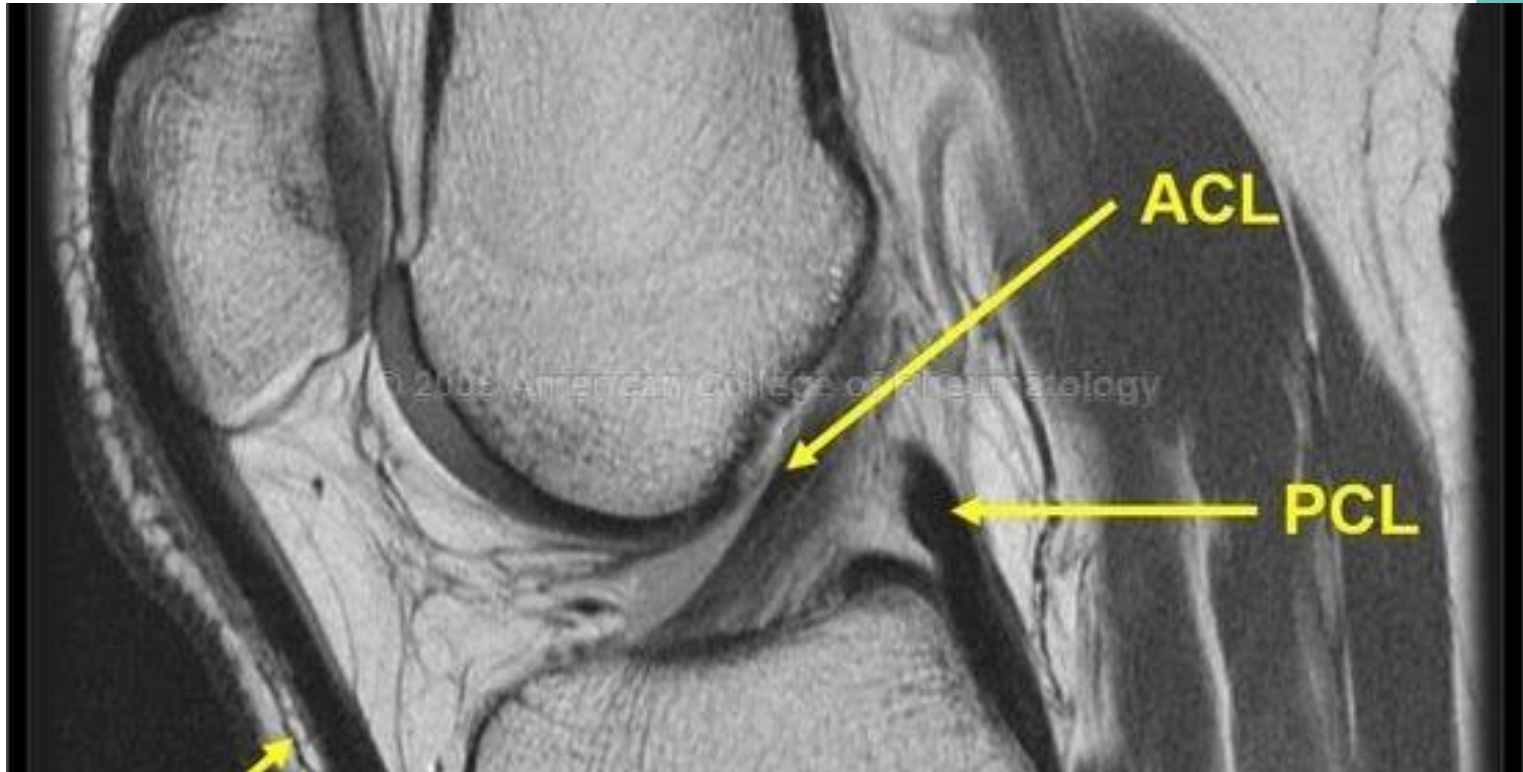

ACL injury – If suspected - Refer

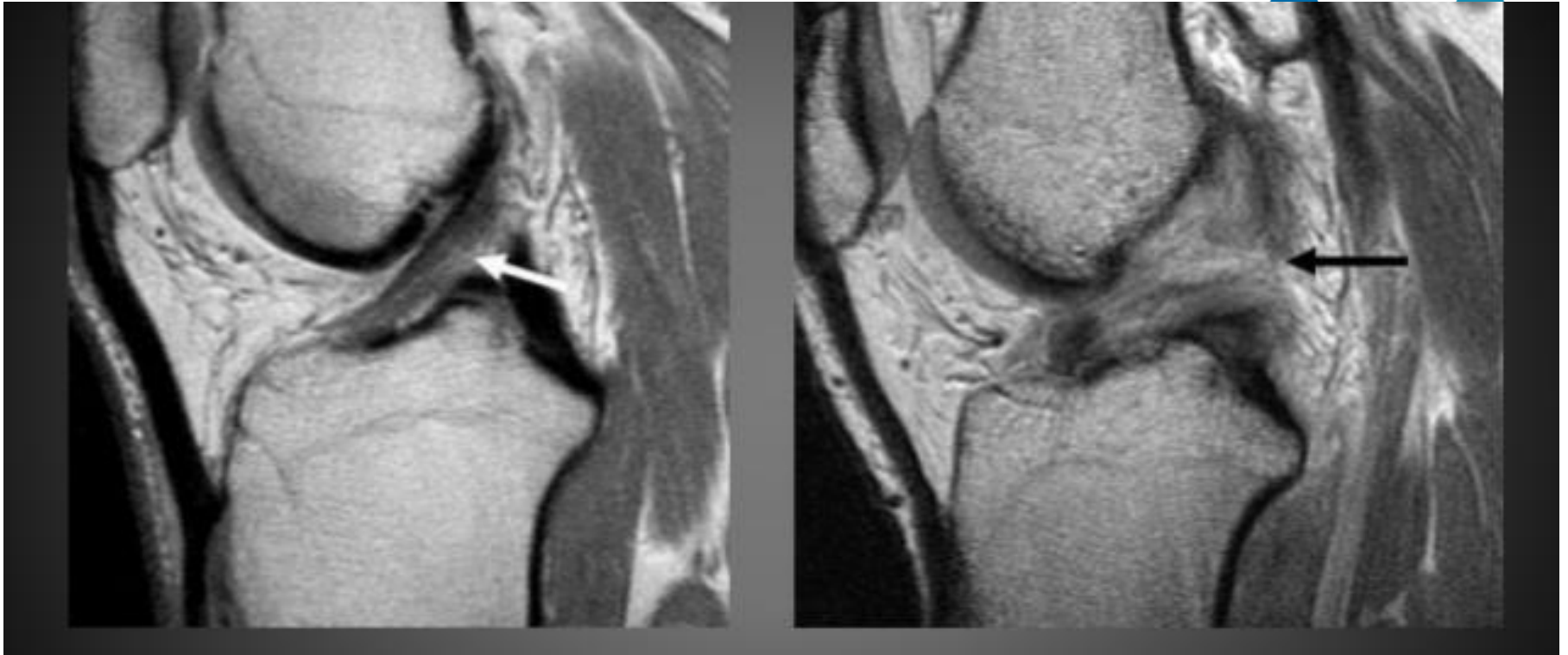


- Xrays
- MRI
- ACL Pre-hab advice

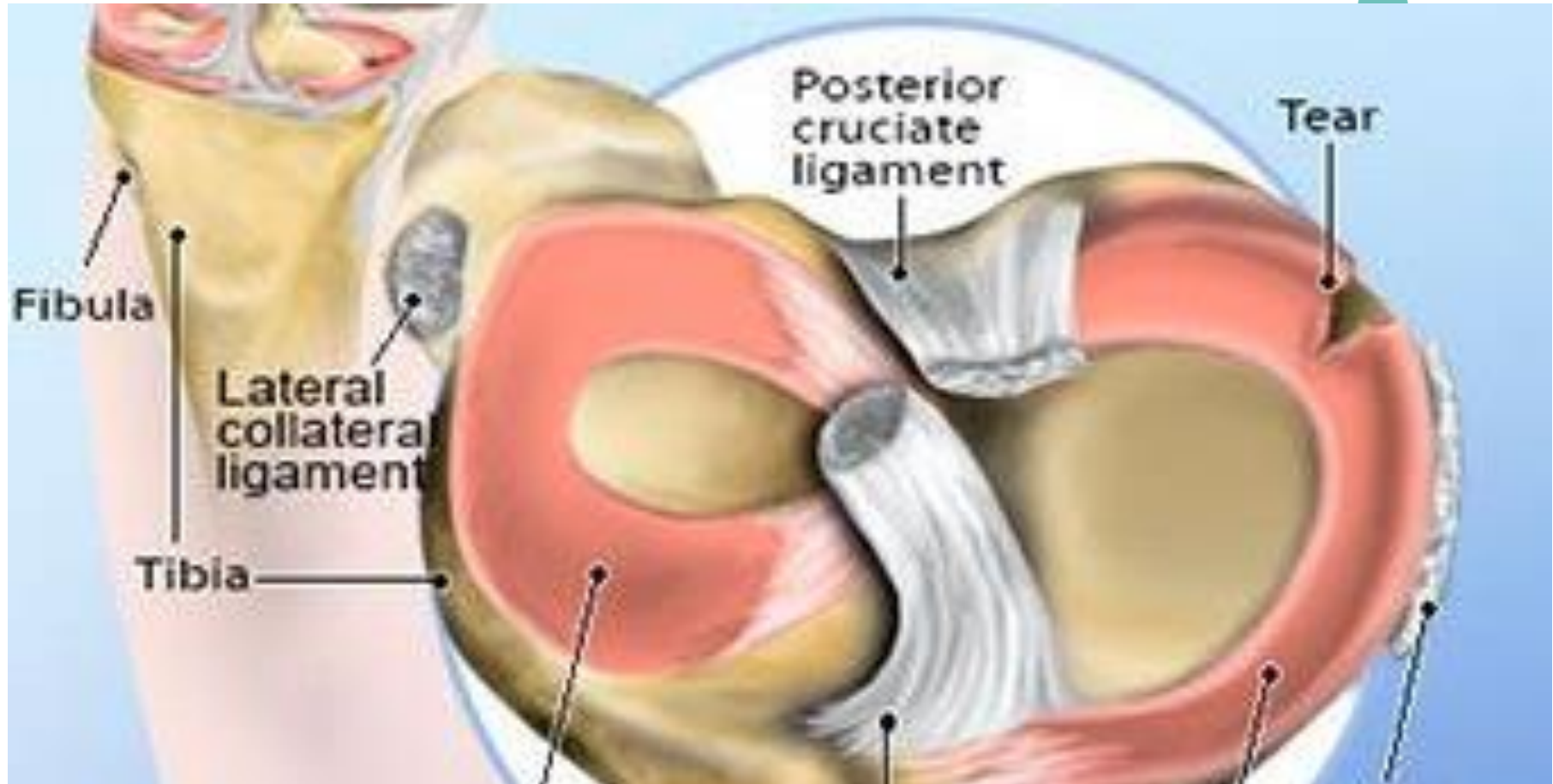
ACL injury – If suspected - Refer



ACL injury – If suspected - Refer



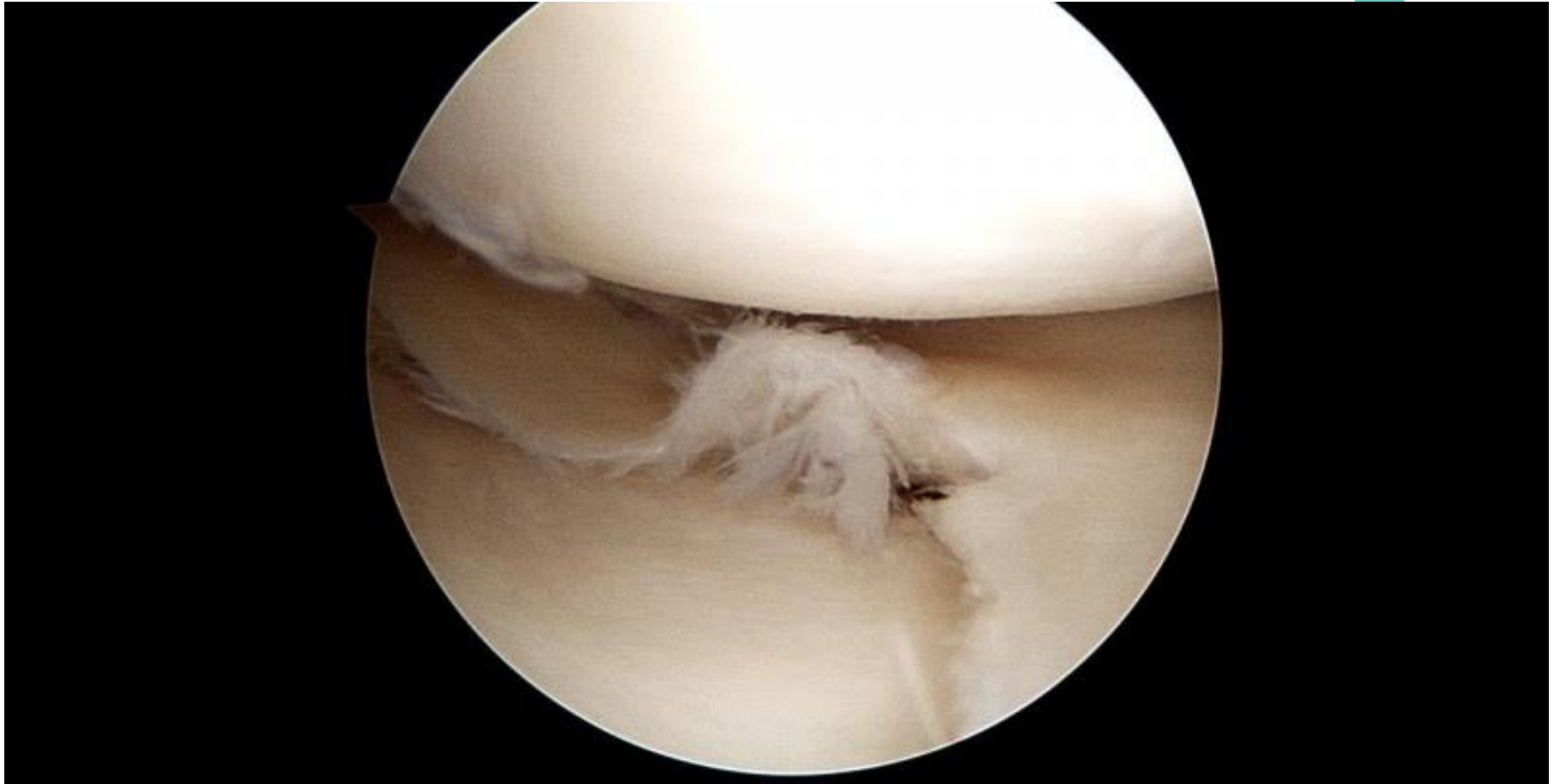ACL injury – Associated with meniscal tear



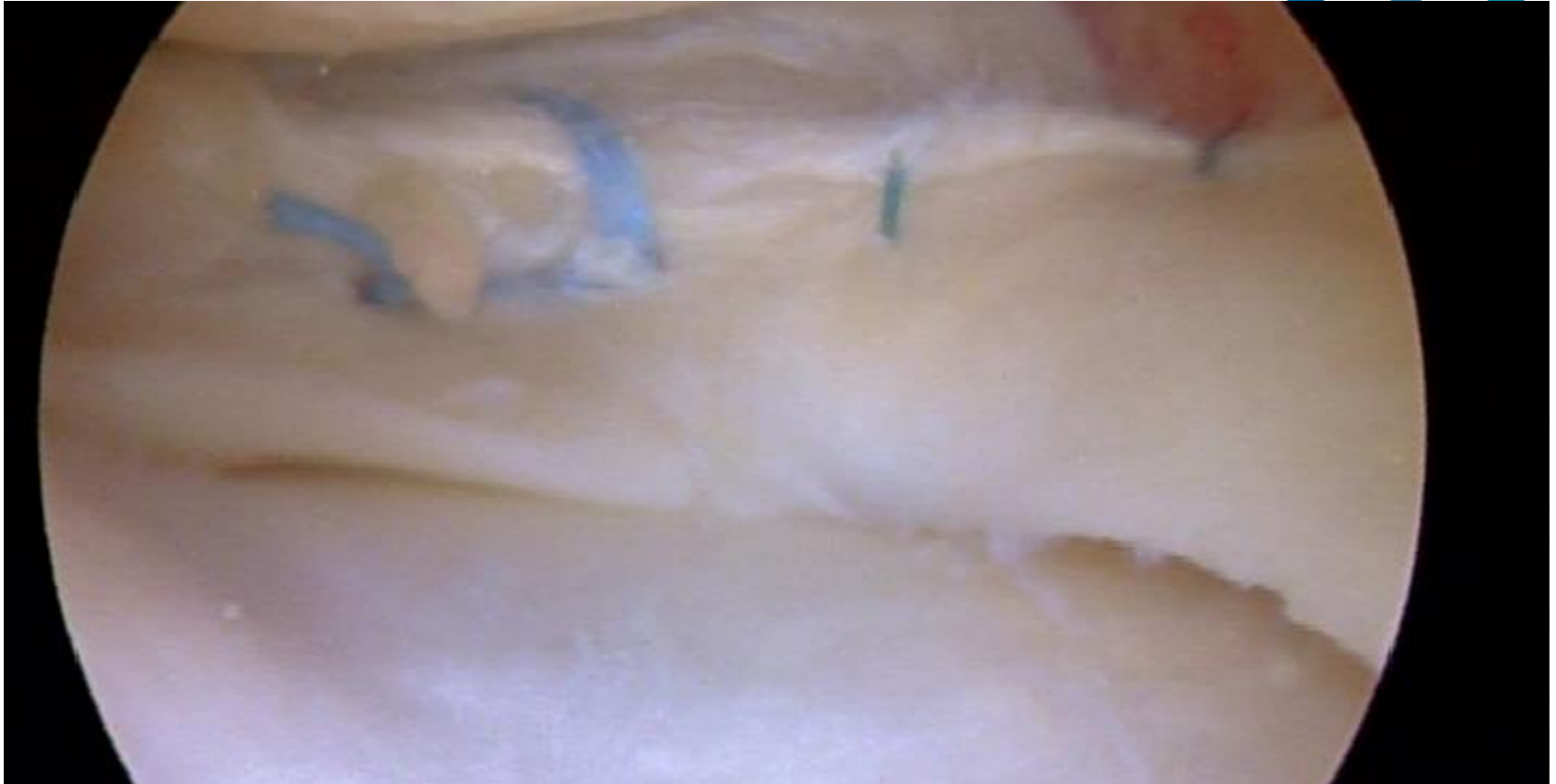Meniscal tear in the over 40's.....



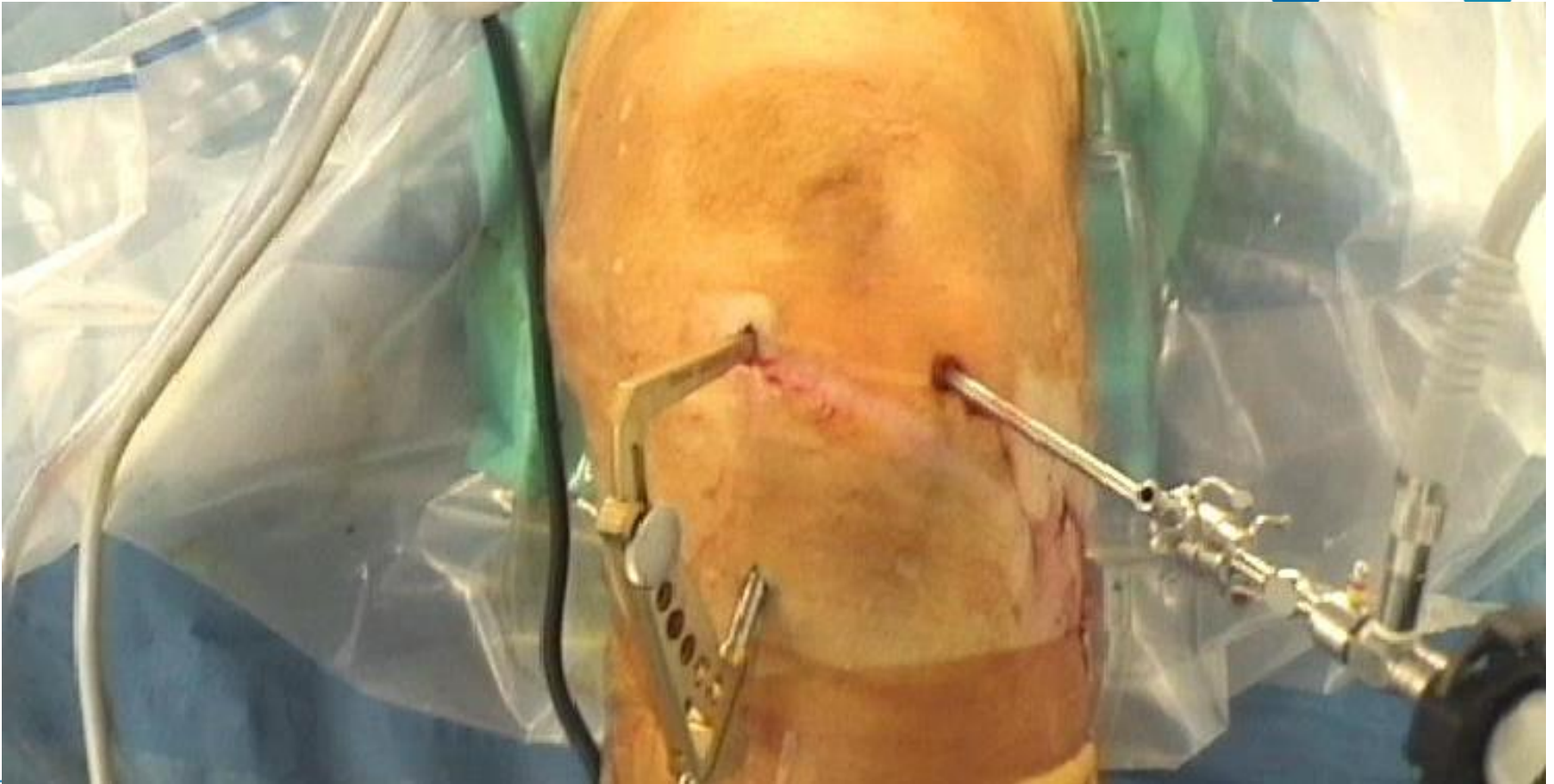Meniscal tear in adults.....



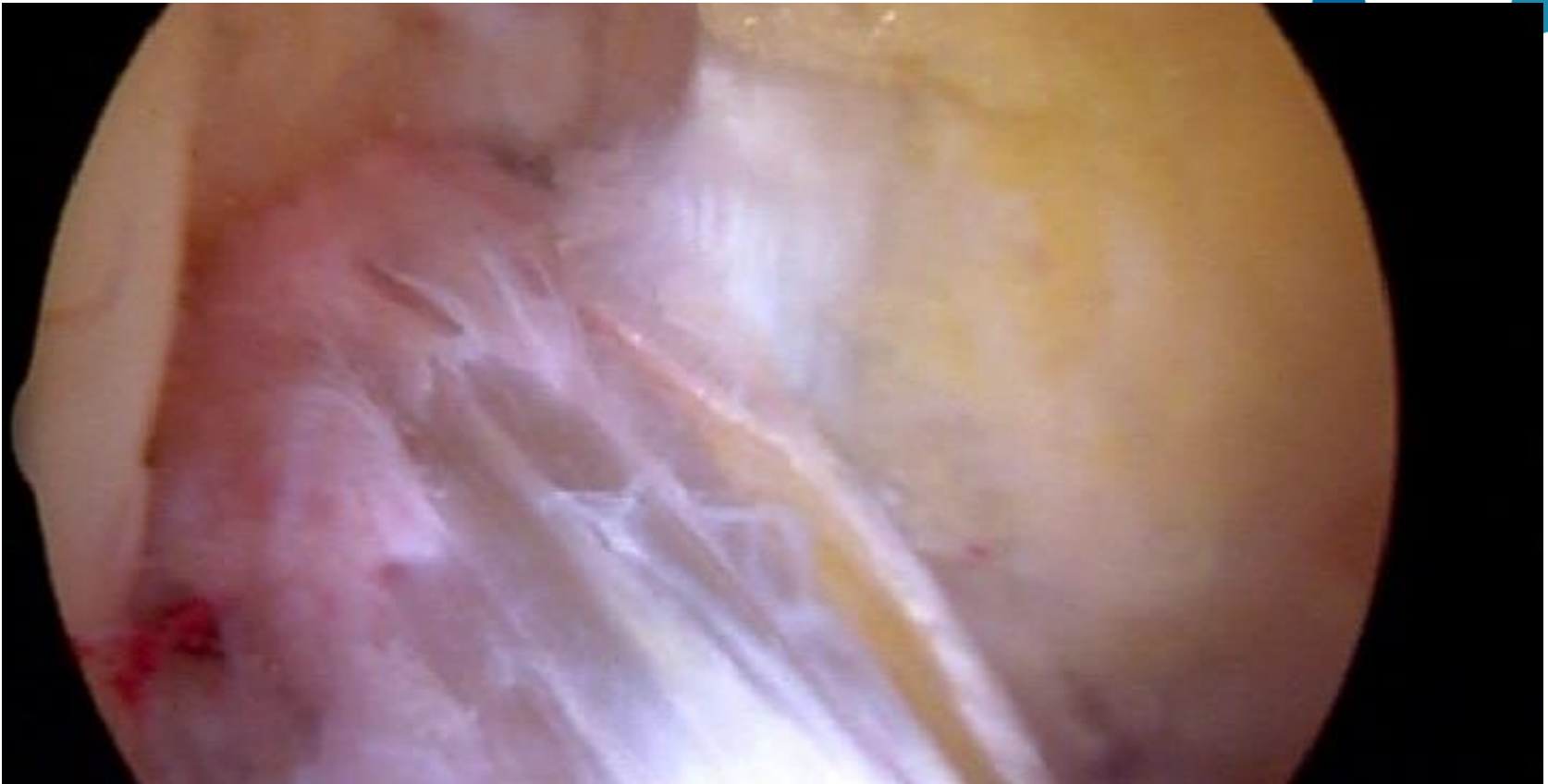
Meniscal tear in adults.....



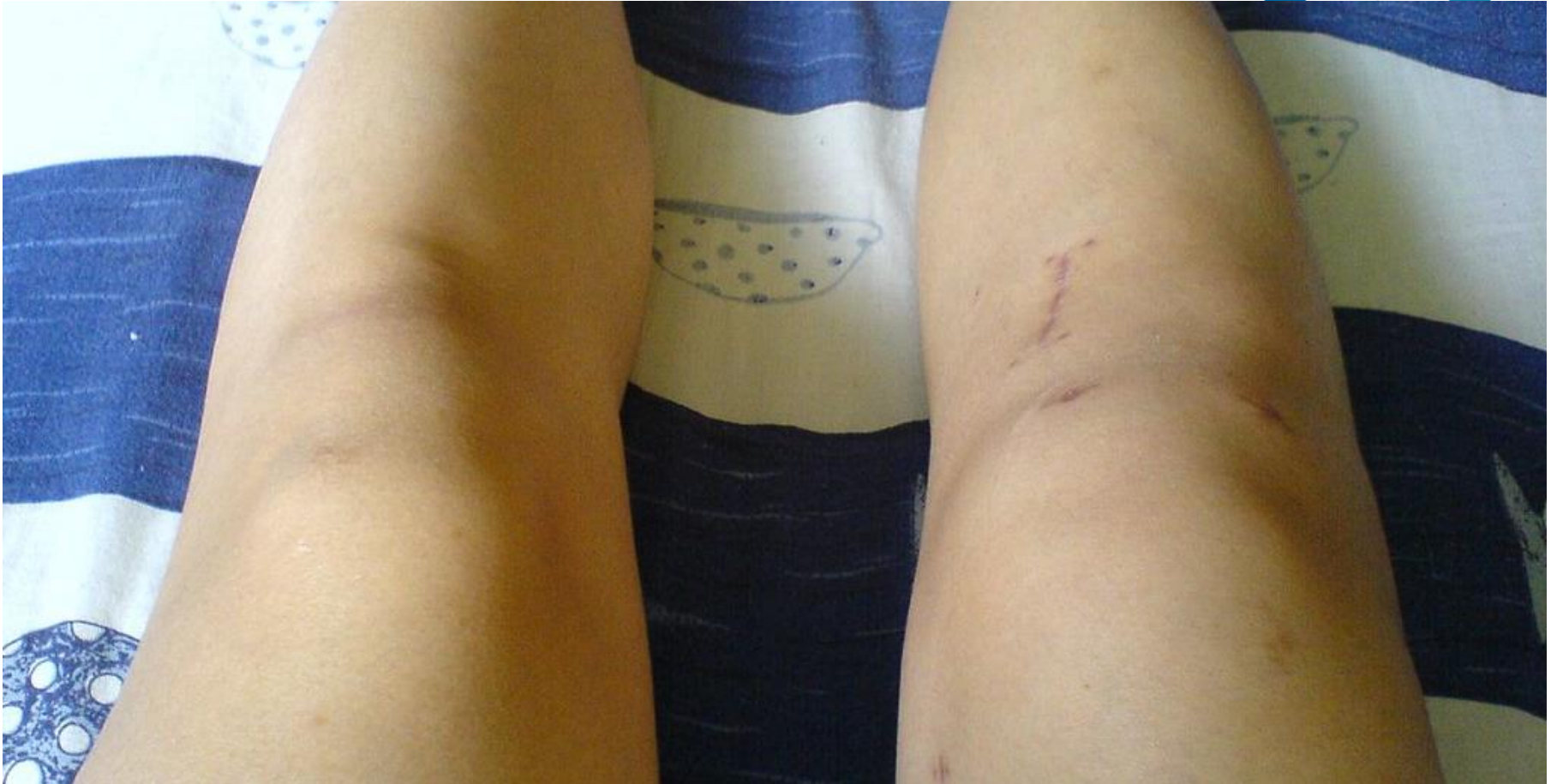Arthroscopic ACL reconstruction



Arthroscopic ACL reconstruction

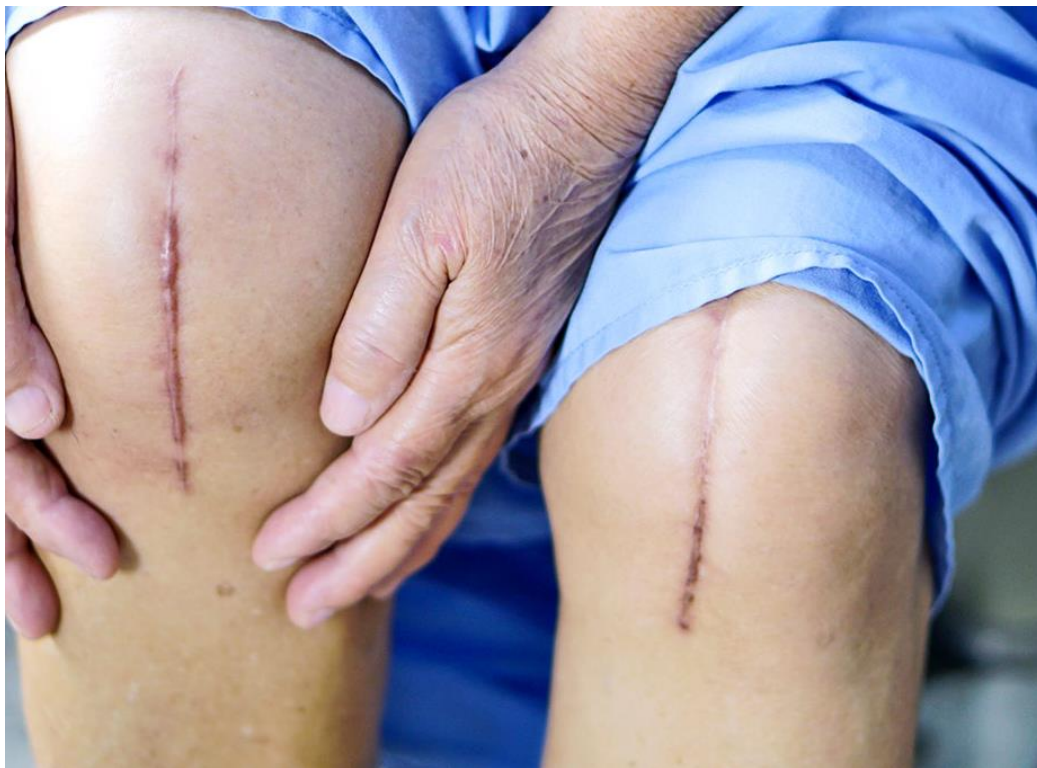

Arthroscopic ACL reconstruction

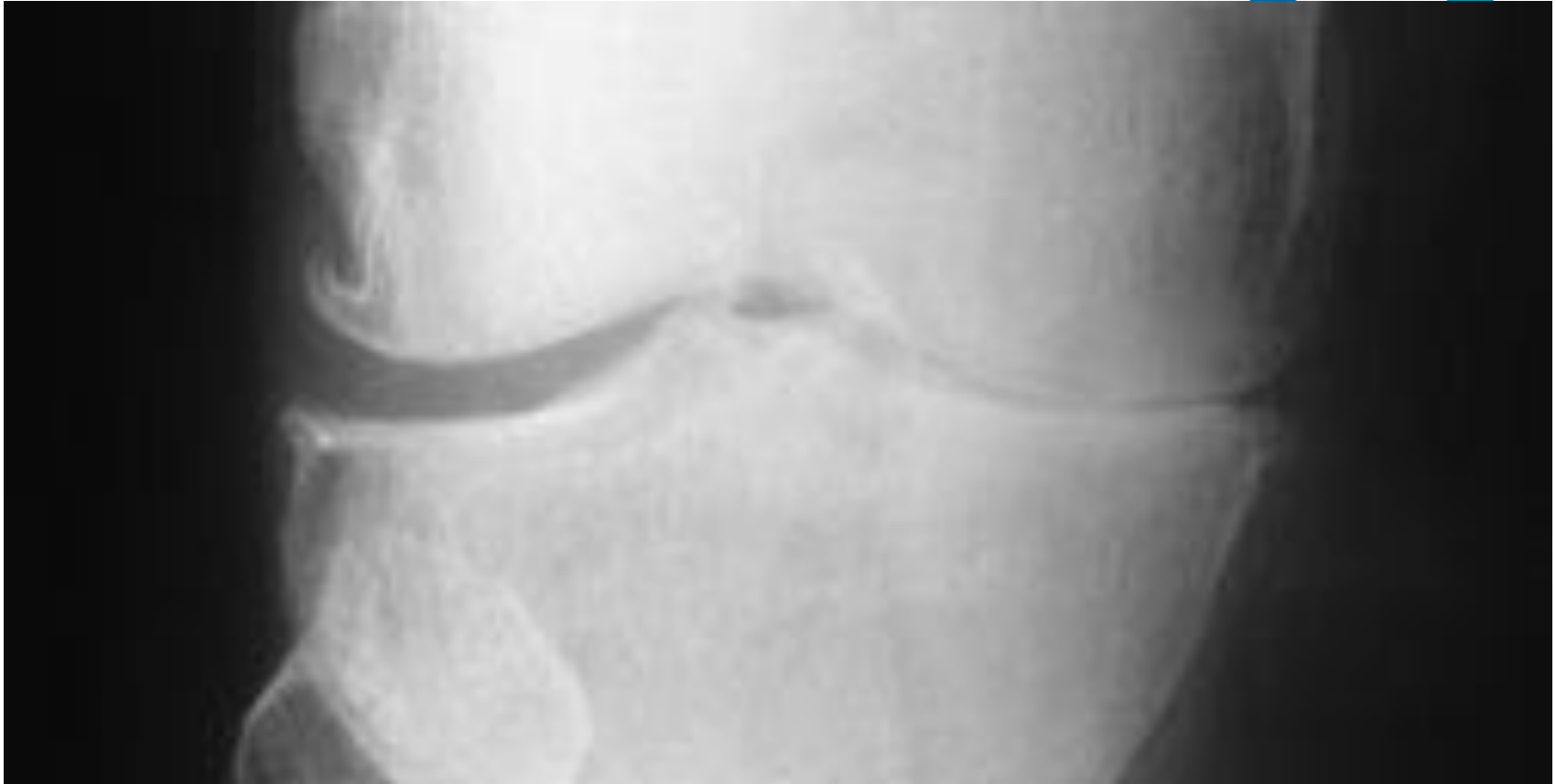

FRIDAY

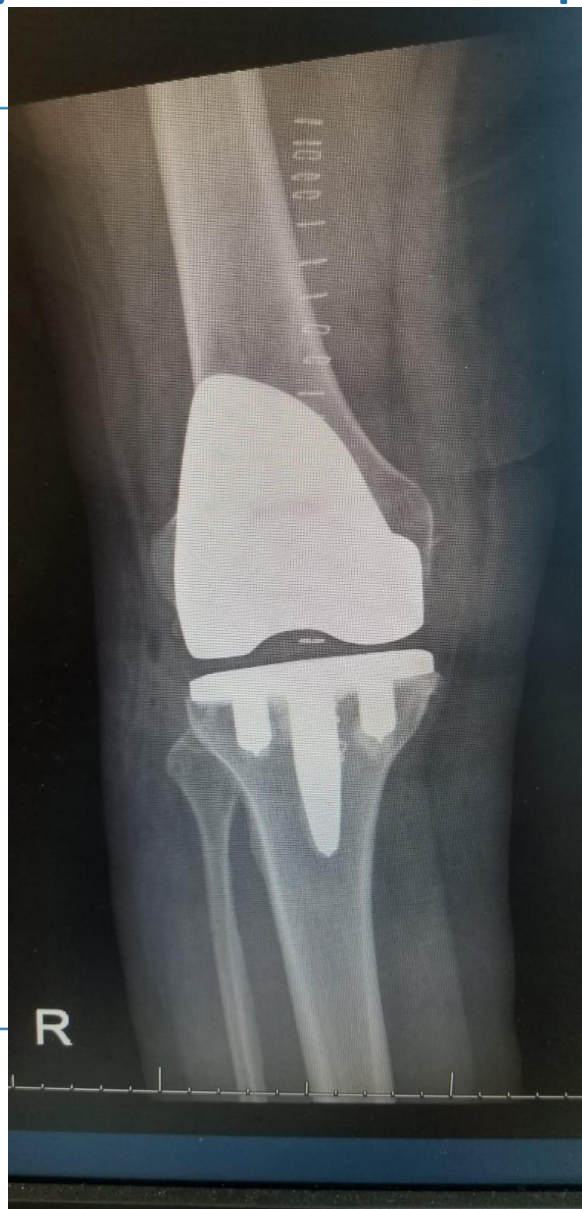75yr old lady – 2 weeks post TKR



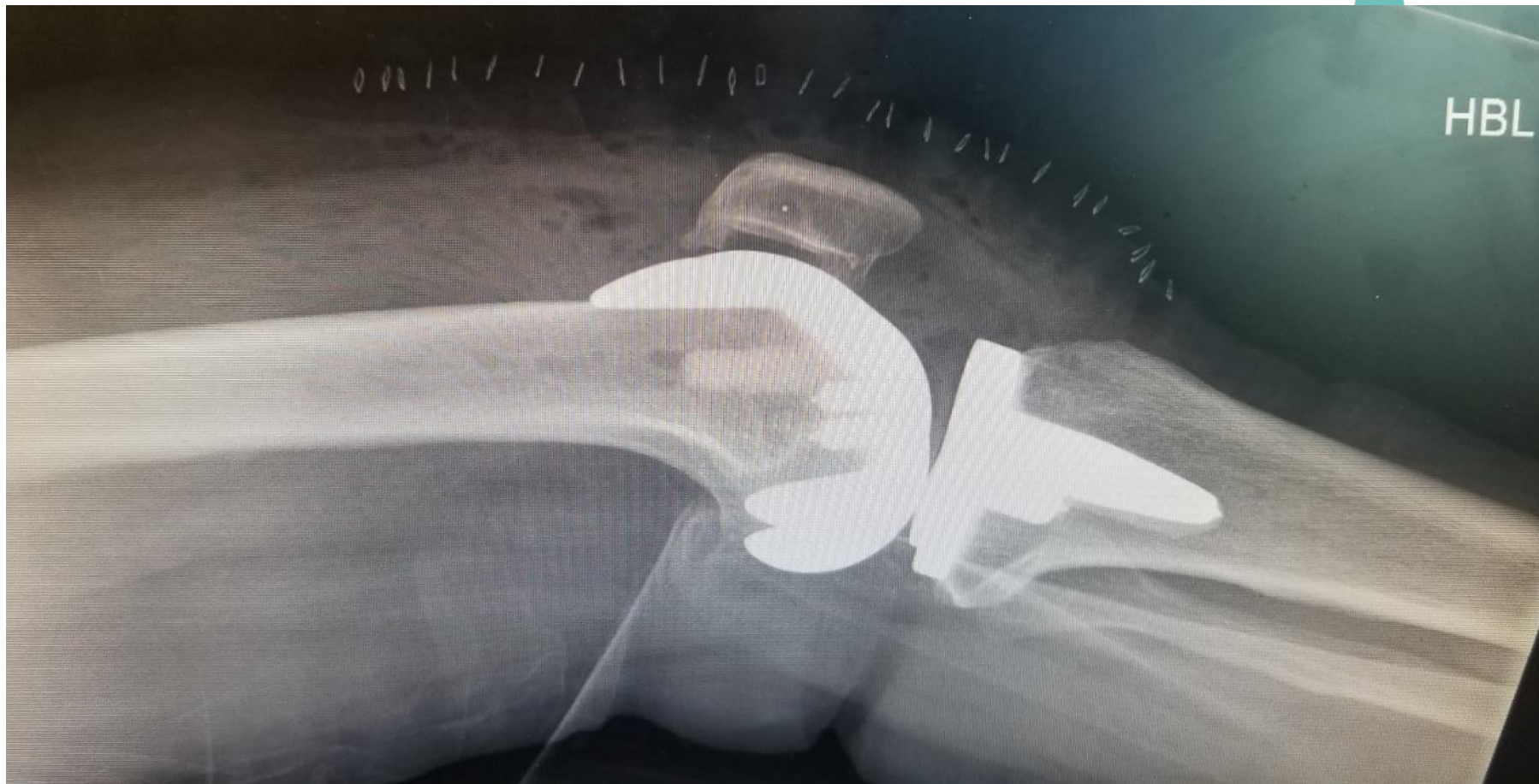75yr old lady – 3 weeks post TKR



75yr old lady – 2 weeks post TKR



75yr old lady – 2 weeks post TKR



75yr old lady – 2 weeks post TKR



- Pain
- Swelling
- Hot to touch
- Numb patch
- Clicking sensation

All Normal

75yr old lady – 2 weeks post TKR



Don't start on Antibiotics

If in doubt just refer and we will see patient ASAP.



Day Surgery Arthroplasty!

Conclusion



Osgood-Schlatter disease = majority can be treated by you.

Osteosarcoma = high index of suspicion and low threshold to refer

ITB friction syndrome = send to physiotherapy

ACL + meniscus injury = refer to us

Post TKR = don't start Antibiotics; if in doubt refer to us

Thank you!