



Surrey Total Health
Your Health. Our Reputation.

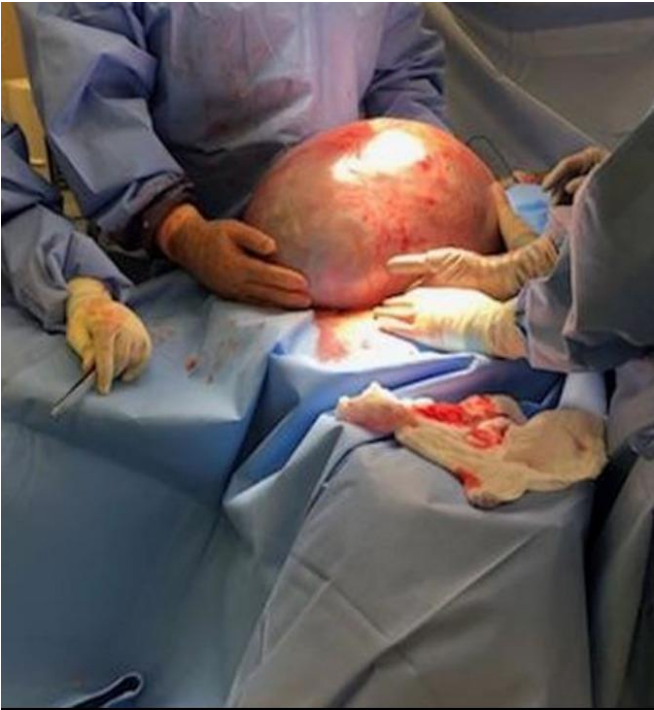Ovarian Cysts – When to Act

Vasileios Minas, PhD, MRCOG

Consultant Gynaecologist and Advanced Laparoscopic Surgeon

Ashford & St. Peter's Hospital

Ovarian Cysts - something to worry about ?





Our Purpose



Do nothing

Re-scan

Refer



Pre/Post-menopausal status



Symptoms
Size of cyst
Nature of cyst



Tumor
markers



Our Purpose



Do nothing

Re-scan

Refer



Pre/Post-menopausal status



Symptoms
Size of cyst
Nature of cyst



Tumor
markers



Our Purpose



Do nothing

Re-scan

Refer



Pre/Post-menopausal status



Symptoms

Size of cyst

Nature of cyst



Tumor
markers



Our Purpose



Do nothing

Re-scan

Refer



Pre/Post-menopausal status



Symptoms

Size of cyst

Nature of cyst



Tumor
markers



Our Purpose



Do nothing

Re-scan

Refer



Pre/Post-menopausal status



Symptoms
Size of cyst

Nature of cyst



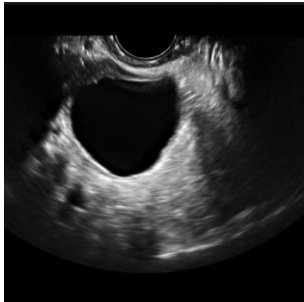
Tumor
markers

Pre-menopause

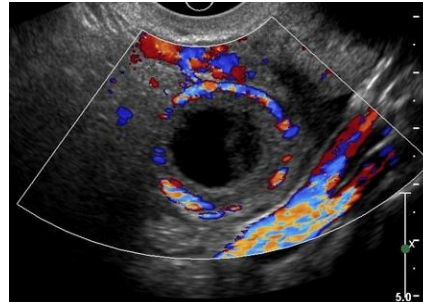


Physiological or Functional cysts

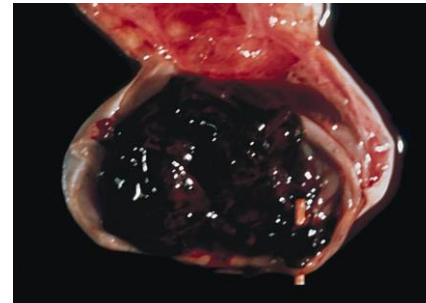
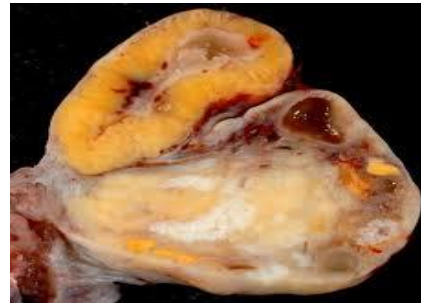
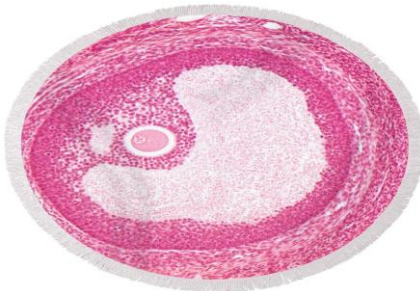
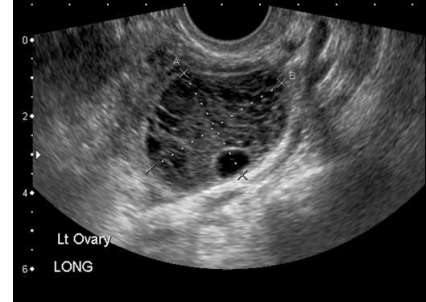
Follicles



Corpus Luteum



Haemorrhagic

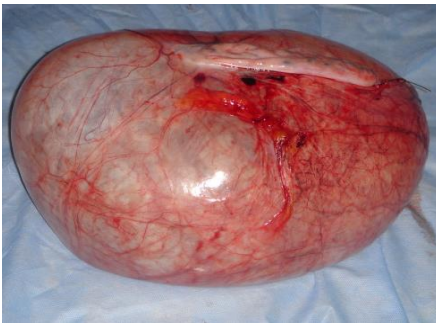
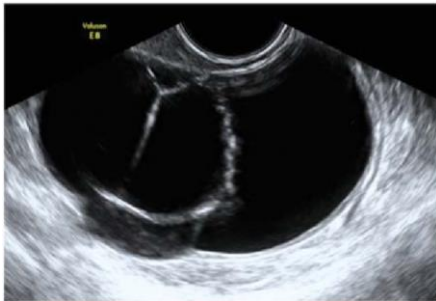

Pre-menopause

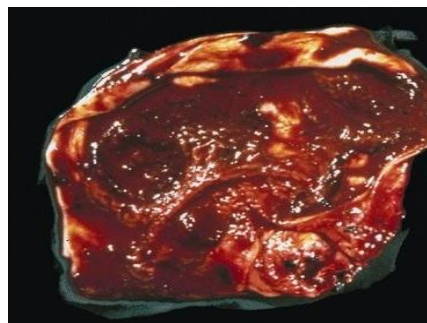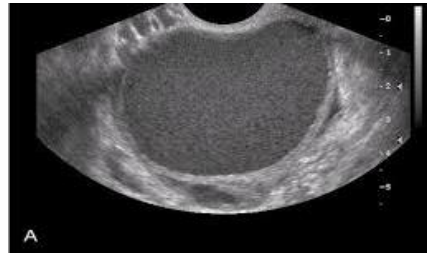


Pathological Cysts

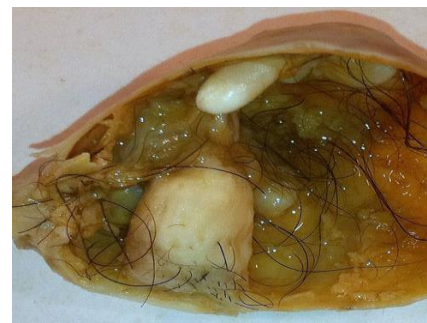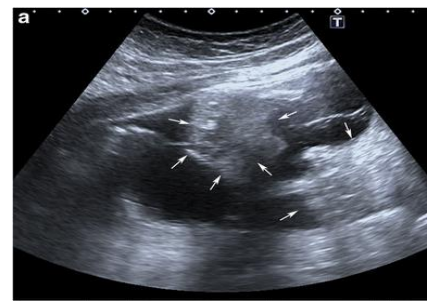
Cystadenoma



Endometrioma



Dermoid or Teratoma



Pre-menopause



Tumor Markers

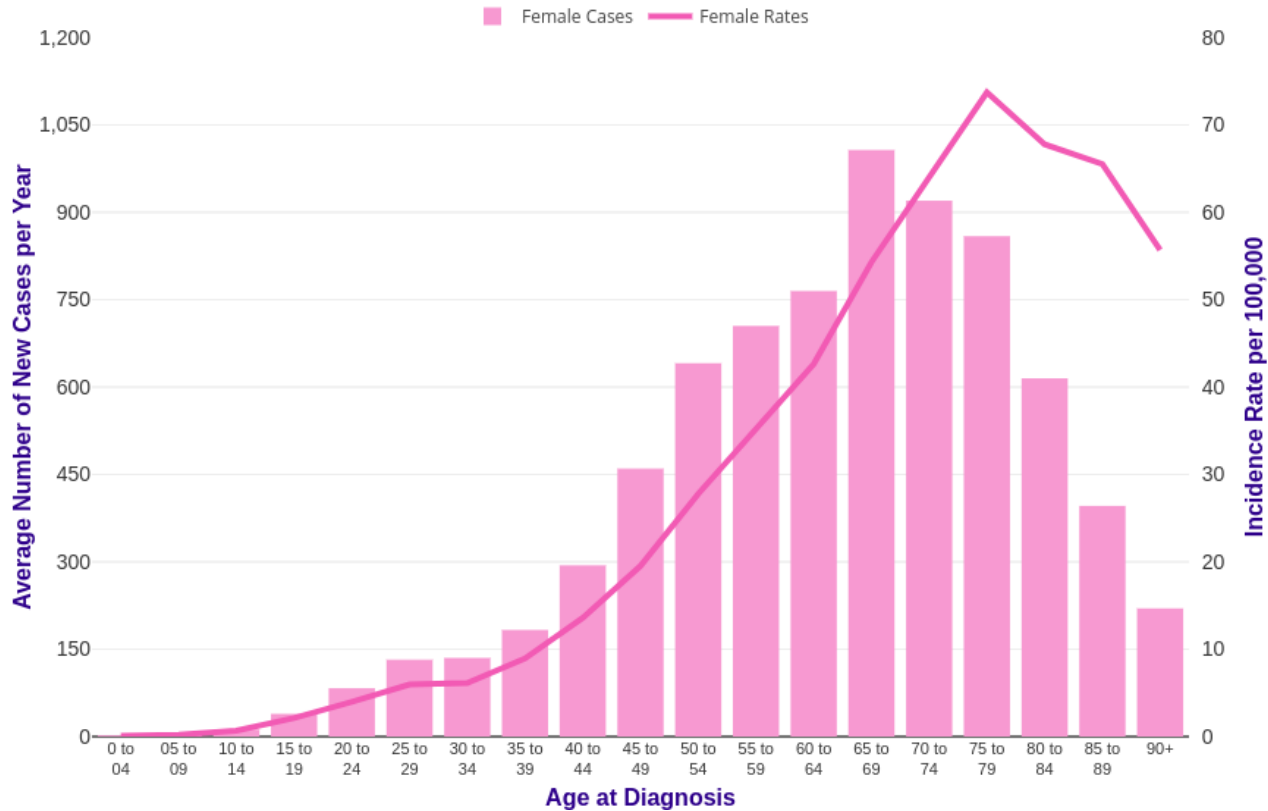
AFP

LDH

HCG

? CA125

Post-menopausal



Post-menopause

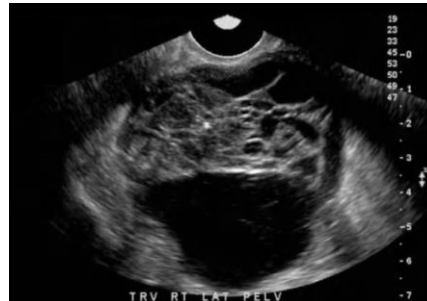


Pathological Cysts

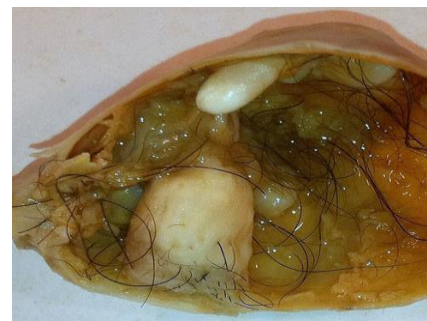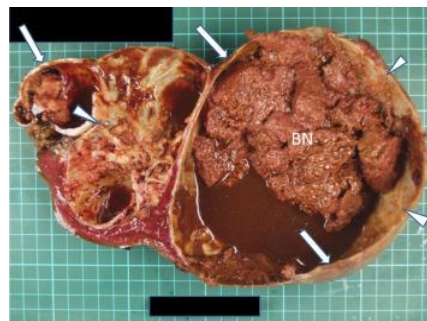
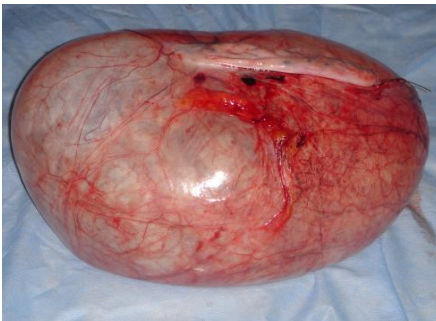
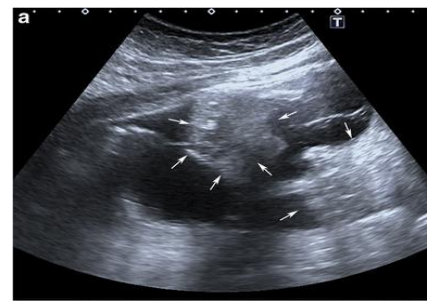
Cystadenoma



CystadenoCa



Dermoid or Teratoma



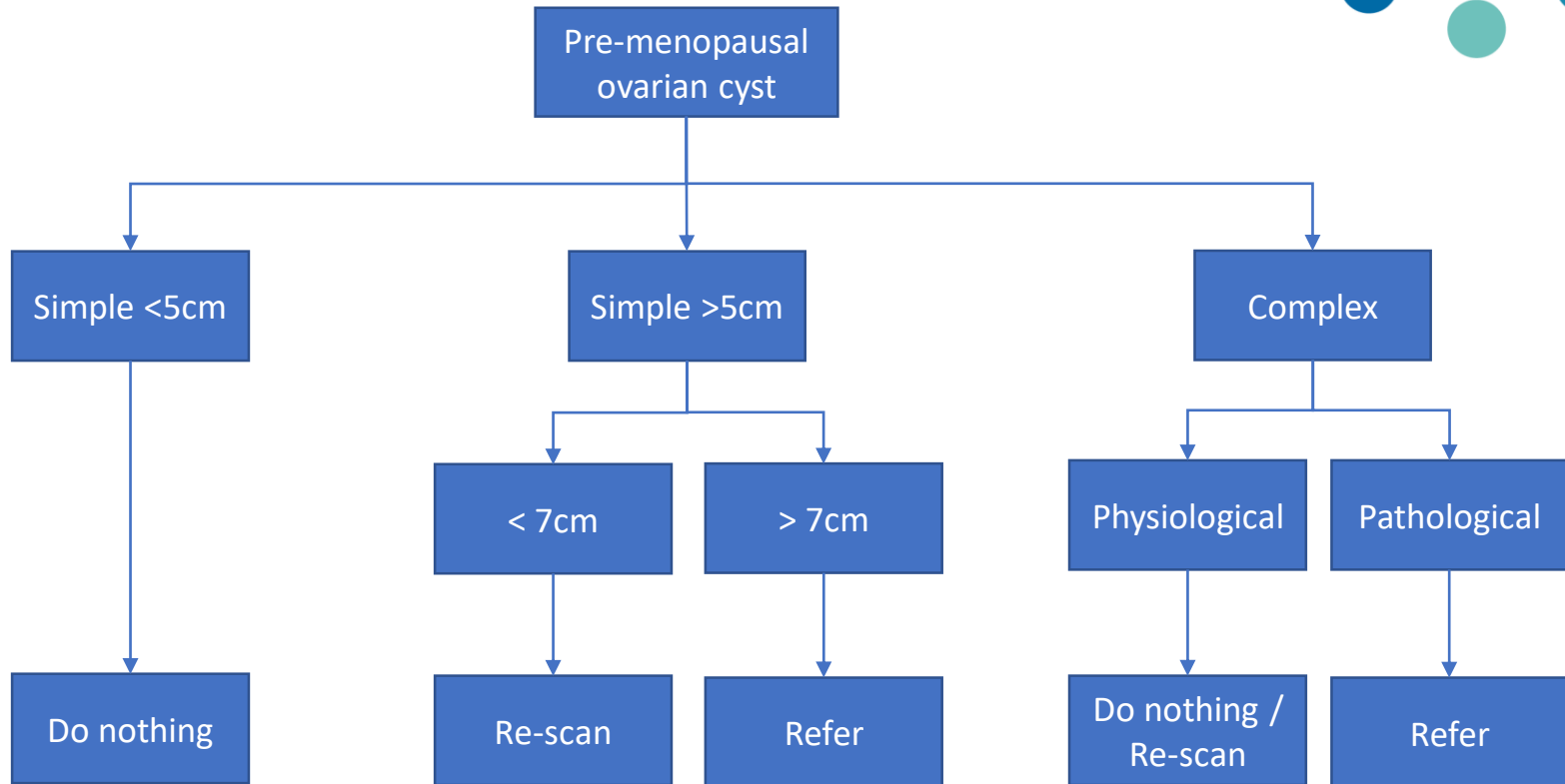
Pre-menopause



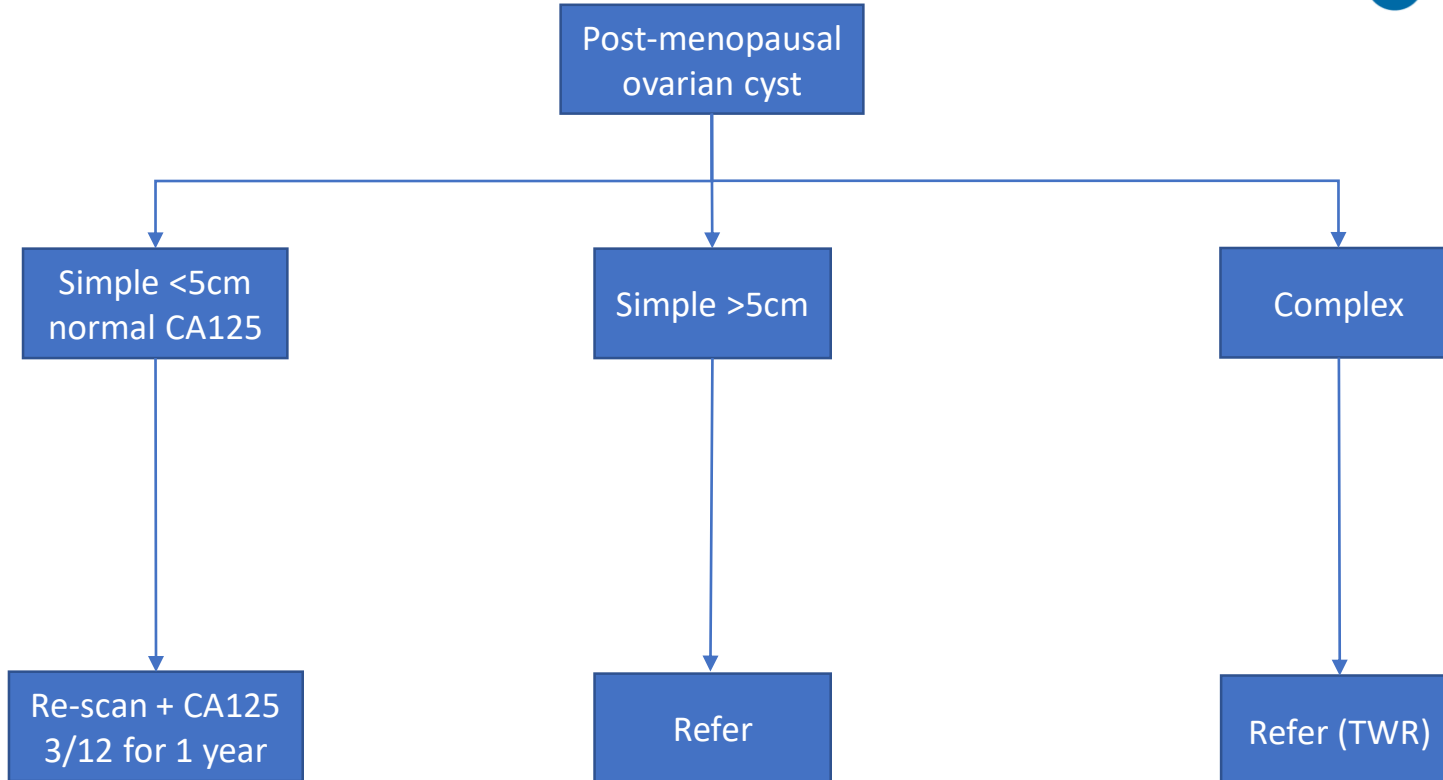
Tumor Markers

CA125

In Summary



In Summary



Thank you. Any Questions ?